

## Jejunal Diverticula Causing Massive Intestinal Bleeding

R. Vilallonga<sup>1</sup>, J.L. Sanchez Garcia<sup>2</sup>, M. Armengol<sup>2</sup>, N. Iordache<sup>3</sup>

<sup>1</sup>Endocrine, metabolic and bariatric Unit, General Surgery Department, University Hospital Vall d'Hebron, Center of Excellence for the EAC-BC, Barcelona, Spain

<sup>2</sup>Colorectal Unit, General Surgery Department, University hospital Vall d'hebron, Barcelona, Spain

<sup>3</sup>Department of General Surgery, "Sf. Ioan" Clinical Hospital, Bucharest, Romania

### Rezumat

#### *Diverticulul jejunal – cauză de sângerare intestinală*

Diverticuliile intestinului subțire sunt formațiuni rar întâlnite. În unele cazuri pot fi asociate cu complicații ca de exemplu sângerare gastrointestinală. Prezentăm cazul unui pacient de 39 de ani cu șoc hemoragic secundar unei sângerări gastrointestinale, recurente. S-au administrat transfuzii de sânge și s-a realizat arteriografie selectivă, evidențiind sângerare activă la nivelul arterei ileocolice. S-a intervenit chirurgical și s-a observat prezența de sânge la nivelul întregului colon și a intestinului subțire până la 40 cm de unghiul Treitz, unde s-au evidențiat de asemenea diverticuli multipli. S-a realizat rezecție intestinală. Deși diverticuliile duodenojejunale nu reprezintă o entitate frecvent întâlnită, ar trebui să avem în vedere această patologie în special în cazurile de hemoragie digestivă superioară recurentă, cum este cazul pacientului nostru.

**Cuvinte cheie:** hemoragie digestivă, diverticuli jejunali, intestin subțire

### Abstract

Small bowel diverticula are rare formations and some are prone to complications such as lower gastrointestinal bleeding. We report the case of a patient with hemorrhagic shock following upper gastrointestinal bleeding. A 39-year-old patient was admitted to the unit for recurrent bleeding. The patient received transfusions and selective arteriography was performed which reported bleeding at the level of the ileocolic artery. Laparotomy was performed and blood was found at the entire colon and small intestine up to 40 cm of Treitz angle where multiple diverticula were visualized. Bowel resection was performed. Although duodeno-jejunal diverticula are rare, a special attention should be paid to this clinical entity as it can be a cause of recurrent upper gastrointestinal bleeding.

**Key words:** gastrointestinal haemorrhage, jejunal diverticulosis, small intestine

---

Corresponding author:

Ramon Vilallonga, M.D.  
General Surgery Department  
Endocrine, Metabolic and Bariatric Unit  
University Hospital Vall d'Hebron  
Passeig de la Vall d'Hebron, 119-129  
08035 Barcelona (Spain)  
Tel: 0034 62642585, Fax: 0034 932746224  
E-mail: vilallongapuy@hotmail.com

### Introduction

Diverticulosis is recognized as the most common etiology of massive lower gastrointestinal bleeding. It is estimated that approximately one third of major lower gastrointestinal bleeding in the elderly is caused by diverticular disease.

### Case report

*A 39 years old patient, who presented with hemorrhagic shock for upper gastrointestinal bleeding was admitted into*

our center. He presented with clinical hemorrhagic shock. The patient had a selective arteriography that was performed to visualize an image suggestive of bleeding at the level of the ileocolic artery. Surgery was performed and endoluminal blood was found at the entire colon and small intestine up to 40 cm of Treitz where multiple diverticula were visualized (Fig. 1). Bowel resection was performed. Postoperatively, the patient had an uneventful recovery and was discharged on day 5.

## Discussion

When a patient has a low the hematocrit and rectal bleeding, a gastrointestinal bleeding should be suspected. This type of bleeding is uncommon and constitutes only 1.4% of all cases of gastrointestinal bleeding (1). Among the most common aetiologies of small bowel bleeding there are arteriovenous malformations, tumors and inflammatory bowel disease such as Crohn's disease. Other possible aetiologies are diverticula, often located in the duodenum and/or jejunum.

Small bowel diverticula are located mostly in the duodenal portion (45%), followed by an ileal region (23%) that includes Meckel's diverticulum. The prevalence of jejunal diverticula was estimated around 0.26% (2). The extent of diverticula varies from few millimetres to more than 10 cm. The prevalence of diverticula in the jejunum is higher and it is attributed to the larger diameter of the jejunal arteries (3). The diverticula are more frequent in men and older people (4).

The aetiology of small bowel diverticula remains uncertain and can lead to an increased intraluminal pressure. Thus, in weak and highly vascularised areas of the small intestine this protrudes the mucosa and serosa of the small intestine. These bulging diverticula match with their mesenteric location. Two mechanisms have been suggested to explain the aetiology of bleeding in the small bowel diverticula. The first refers to ulceration of the mucosa and the second to a dilation of blood vessels in the bag distension or irritation from intestinal contents (5).

Typically, small bowel diverticula tend to be asymptomatic. Still, when symptoms occur, the most common presentation is abdominal pain (49%) or gastrointestinal bleeding (29%) (6). Some studies found an incidence of small bowel diverticula ranging from 0.07% to 0.7% in radiological studies (7). The most common location of these diverticula is on the mesenteric border of the small intestine. Meckel's diverticulum occurs on the antimesenteric border.

Serious complications have been reported in the diverticula of small intestine although these are rare. These include the perforation, inflammation of these diverticula, volvulus, bacterial overgrowth, the intussusception and finally, as in our case report, massive hemorrhage. The most common complication is diverticulitis, with or without perforation, which has been described with an incidence ranging from 2.3% to 6.4% of cases (3,8,9). This inflammation of the diverticula may mimic other intraabdominal processes of irritation such as acute appendicitis, acute cholecystitis or perforated ulcer colonic diverticulitis (10). It is remarkable that the small bowel perforation is often different from the large intestine, this being

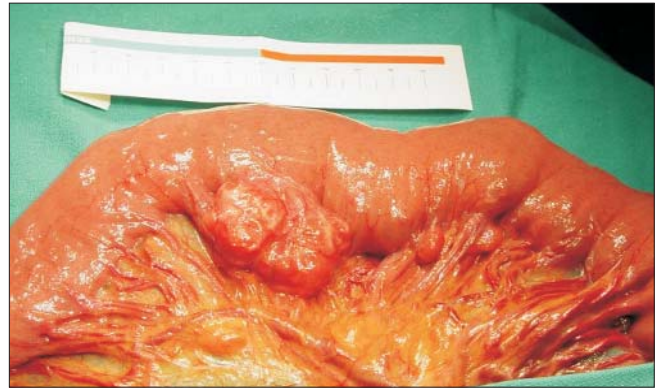


Figure 1. Image of the jejunal diverticula

slower and developing peritonitis with a lapse of time. A rare complication is the formation of a jejunocolic fistula caused by inflammation and perforation of the diverticulum and penetration of foreign bodies (11).

The initial diagnostic management for these patients includes gastroscopy and colonoscopy. However, even when the fibrocolonoscopy or the gastroscopy show any bleeding, further investigations as the abdominal CT are needed (12).

The barium X-ray study of the small intestine is of special interest in diagnosing small bowel diverticula. When bleeding of the diverticula occurs, which manifests as melena or rectal bleeding, the preoperative diagnosis of small bowel bleeding is often difficult. (8,11,13,14) It has also been described bleeding with anemia and chronic poor response to iron treatment. The presence of colonic diverticulosis contributes to increased diagnostic problem (9). Some studies have indicated surgical and diagnostic difficulties when one tries to study the gastrointestinal bleeding associated with diverticula (15,16). The preoperative diagnosis should be established by endoscopy, selective arteriography or scintigraphy labeled neutrophils. The study of the small intestine with barium contrast is in dispute, with the presence of false positives. Enteroscopy has also been proposed as a method of diagnostic test. However, a part of the small intestine still remains unexplored. Some studies proposed endoscopic capsules that capture images during their passage through the intestine, subsequently being processed and analyzed in detail (17).

The treatment of choice is surgery with wide resection of the affected segment including the small bowel diverticula.

## Conclusion

In the light of the above, we can conclude that small bowel diverticula should be included in the differential diagnosis of a patient with an unexplained gastrointestinal bleeding, small bowel obstruction and acute abdominal pain.

## Acknowledgements

The Dr. Ramon Vilallonga Foundation has participated with the financial support to prepare the manuscript. ([www.fundacionramonvilallonga.org](http://www.fundacionramonvilallonga.org)). The authors want to

thank Dra. Andrea Ciudin for his transcription to the Romanian language of the paper.

## References

1. Brief DK, Botsford TW. Primary bleeding from the small intestine in adults. The surgical management. *JAMA*. 1963; 184:18-22.
2. Feldman M, Scharschmidt BF, Sleisenger MH, ed. *Enfermedades gastrointestinales y hepáticas. Fisiopatología, diagnóstico y tratamiento*. 6ª Ed. Philadelphia: WB Saunders; 1998.
3. Tsiotos GG, Farnell MB, Ilstrup DM. Nonmeckelian jejunal or ileal diverticulosis: an analysis of 112 cases. *Surgery*. 1994;116(4):726-31; discussion 731-2.
4. Shanmugam RP, Shivakumar P. A rare complication of jejunal diverticulosis. *Trop Gastroenterol*. 2006;27(3):134-5.
5. Silen W, Brown WH, Orloff MJ, Watkins DH. Complications of jejunal diverticulosis. A report of three cases. *Arch Surg*. 1960;80:597-601.
6. Chiu EJ, Shyr YM, Su CH, Wu CW, Lui WY. Diverticular disease of the small bowel. *Hepatogastroenterology*. 2000; 47(31):181-4.
7. Orr IM, Russell JY. Diverticulosis of the jejunum—a clinical entity. *Br J Surg*. 1951;39(154):139-47.
8. Wilcox RD, Shatney CH. Surgical implications of jejunal diverticula. *South Med J*. 1988;81(11):1386-91.
9. Palder SB, Frey CB. Jejunal diverticulosis. *Arch Surg*. 1988; 123(7):889-94.
10. Kouraklis G, Mantas D, Glivanou A, Kouskos E, Raftopoulos J, Karatzas G. Diverticular disease of the small bowel: report of 27 cases. *Int Surg*. 2001;86(4):235-9.
11. Shaw JH. Perforated jejunal diverticulum due to foreign body. *N Z Med J*. 1980;91(660):384-5.
12. Hibbeln JF, Gorodetsky AA, Wilbur AC. Perforated jejunal diverticulum: CT diagnosis. *Abdom Imaging*. 1995;20(1):29-30.
13. Rodriguez HE, Ziauddin MF, Quiros ED, Brown AM, Podbielski FJ. Jejunal diverticulosis and gastrointestinal bleeding. *J Clin Gastroenterol*. 2001;33(5):412-4.
14. Brasoveanu V, David L, Buga I, Popescu I. A rare cause of lower digestive hemorrhage—jejunal diverticulosis. *Chirurgia (Bucur)*. 2005;100(4):369-72. Romanian
15. Balducci G, Dente M, Cosenza G, Mercantini P, Salvi PF. Multiple giant diverticula of the foregut causing upper gastrointestinal obstruction. *World J Gastroenterol*. 2008; 14(20):3259-61.
16. Wilcox RD, Shatney CH. Massive rectal bleeding from jejunal diverticula. *Surg Gynecol Obstet*. 1987;165(5):425-8.
17. Gong F, Swain P, Mills T. Wireless endoscopy. *Gastrointest Endosc*. 2000;51(6):725-9.